

MRI visibility of gold fiducial markers for image-guided radiotherapy for rectal cancer

R.P.J. van den Ende¹, L.S. Rigter², E.M. Kerkhof¹, E.L. van Persijn van Meerten³, E.C. Rijkmans¹, D.M.J. Lambregts⁴, B. van triest⁵, M.E. van Leerdam², M. Staring⁶, C.A.M. Marijnen¹, U.A. van der Heide^{1,5}

¹Department of Radiation Oncology, Leiden University Medical Center, Leiden, the Netherlands

²Department of Gastroenterology, Netherlands Cancer Institute, Amsterdam, the Netherlands

³Department of Radiology, Leiden University Medical Center, Leiden, the Netherlands

⁴Department of Radiology, the Netherlands Cancer Institute, Amsterdam, the Netherlands

⁵Department of Radiation Oncology, Netherlands Cancer Institute, Amsterdam, the Netherlands

⁶Division of Image Processing, Department of Radiology, Leiden University Medical Center, Leiden, The Netherlands

Purpose/objective

In rectal cancer patients with complete clinical response an organ-preservation strategy seems safe. Dose response analyses suggest that higher tumor doses result in higher complete response rates. Tumor dose can be increased by applying a boost with external beam radiotherapy, endorectal brachytherapy or contact therapy. With position verification using CT, CBCT or a radiograph, verification of tumor position is difficult due to limited soft tissue contrast. Fiducial markers can be used as a surrogate for tumor position, after their position relative to the tumor is established on MRI. The aim of this study was to evaluate the MRI visibility of different gold fiducial markers implanted in the tumor, rectal wall or mesorectum.

Material/methods

We included 20 rectal cancer patients who received neoadjuvant (chemo)radiotherapy. Three or four markers were inserted in the tumor, rectal wall or mesorectum by sigmoidoscopy or endoscopic-ultrasonography. We tested 4 marker types (Visicoil (0.5x5 mm and 0.75x5 mm)[IBA Dosimetry, GmbH, Germany], Cook 0.64x3.4 mm [Cook Medical, Limerick, Ireland] and Gold Anchor 0.28x20 mm [Naslund Medical AB, Sweden]), each placed in 5 patients. Two radiologists and two radiation oncologists were blinded for marker type and identified marker locations on MRI in two scenarios: without (scenario A) and with (scenario B) a rigidly registered CT or CBCT with markers available to aid in identifying the marker locations on MRI. Included MRI sequences were a transverse and a sagittal T2-TSE, a T1 3D with short TE (1.6–2.5 ms), a T1 3D with long TE (5–

15 ms) and a transverse B0 map. Observers labeled marker positions on the sequence on which the marker could most accurately be identified. In addition, the observers graded the visibility of each identified marker on each sequence (0=not visible, 1=poor/average, 2=good/excellent). A marker was defined to be consistently identified if at least three observers labeled that marker on the same position on MRI.

Results

Of the 64 inserted markers, 41 were still present at the time of MRI as determined on corresponding CT or CBCT. Table 1 summarizes the results for scenario B. The Gold Anchor marker was the most consistently identified marker (9 out of 12). In comparison, in scenario A only 4 out of 12 present Gold Anchor markers were consistently identified. The consistently identified Gold Anchor markers were best visible on the T1 3D (long TE) sequence (86% good/excellent) and 73% were labeled on that sequence. The markers were least visible on both T2-TSE sequences (43-46% good/excellent). Examples of the Gold Anchor marker on the different MRI sequences are shown in Figure 1.

Conclusion

The Gold Anchor marker was the best visible marker on MRI as it was the most consistently identified marker. The use of a rigidly registered CT or CBCT improves marker identification on MRI. Standard anatomical MRI sequences are not sufficient to identify markers, it is therefore recommended to include a T1 3D (long TE) sequence.

TABLE 1. Number of consistent and inconsistent identifications for each marker type in scenario B. Numbers between brackets indicate the maximum possible number of correct identifications by 4 observers.

	Visicoil 0.5	Visicoil 0.75	Cook	Gold Anchor
Number of markers present on corresponding CT or CBCT	9	9	11	12
Total number of identifications by 4 observers	23 (36)	35 (36)	24 (44)	46 (48)
Inconsistent identifications	20	19	20	18
Consistent identifications	3	16	4	28
Which represent number of consistently identified markers	1	5	1	9

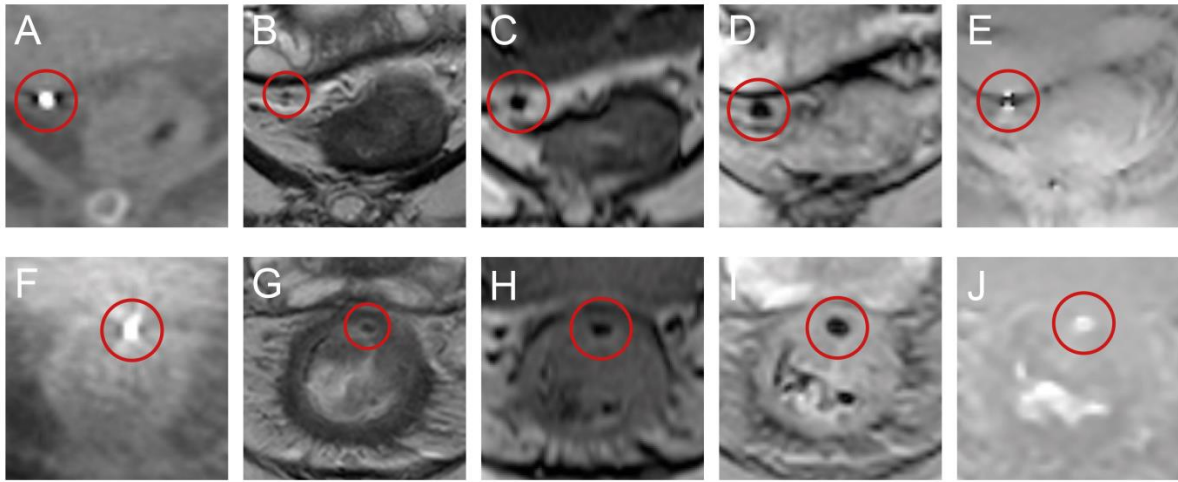


FIGURE 1. Examples of consistently identified Gold Anchor markers in two patients. One in the mesorectal fat (A-E) and one in the rectal wall at the site of the tumor (F-J) on CBCT (A+F), T2-TSE (B+G), T1 3D (short TE) (C+H), T1 3D (long TE) (D+I) and B0 (E+J).